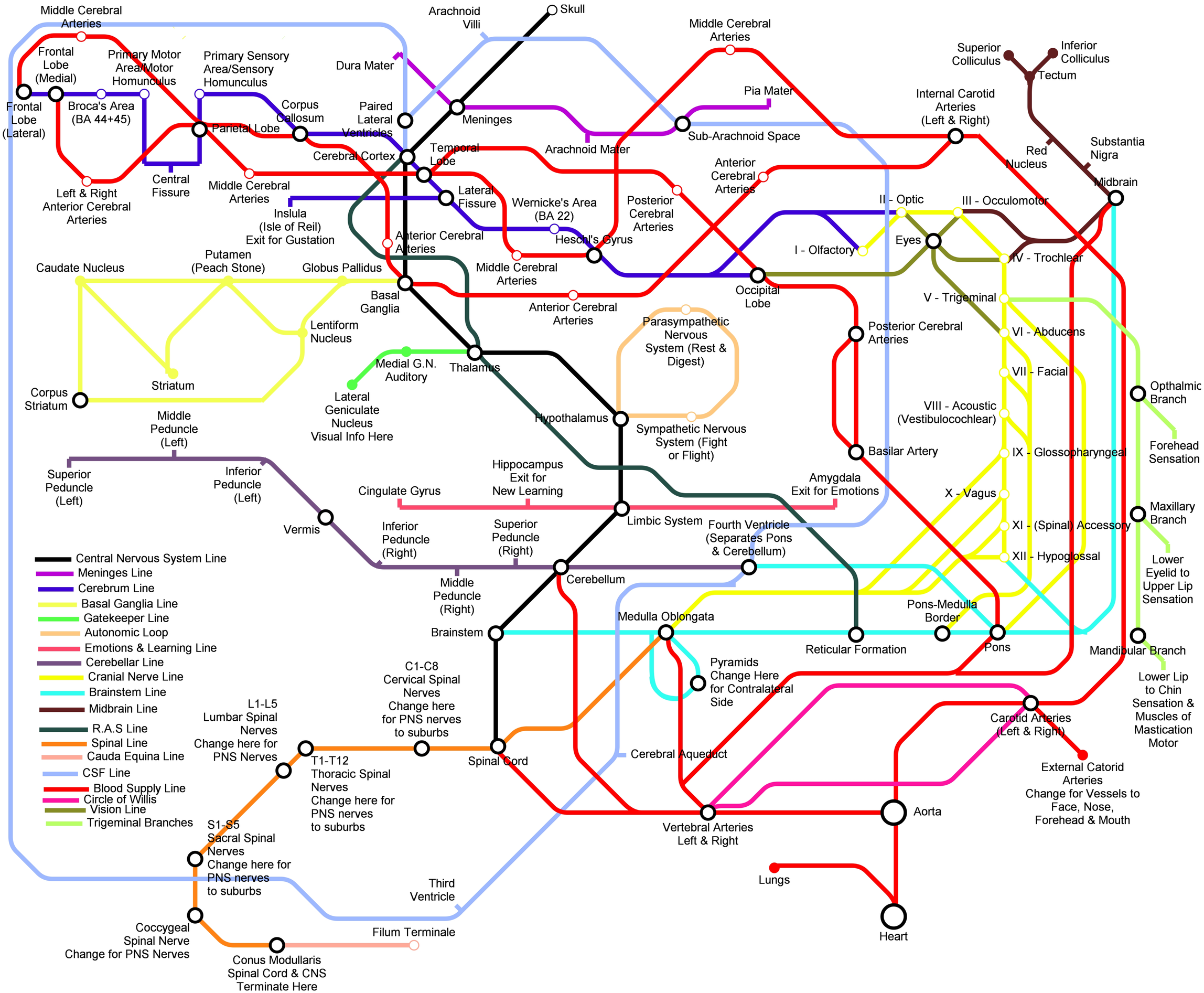
Middle Cerebral Arteries
Frontal Lobe (Medial)
Primary Motor Area/Motor Homunculus
Primary Sensory Area/Sensory Homunculus
Frontal Lobe (Lateral)
Broca's Area (BA 44+45)
Parietal Lobe
Corpus Callosum
Left & Right Anterior Cerebral Arteries
Central Fissure
Middle Cerebral Arteries
Insula (Isle of Reil) Exit for Gustation
Caudate Nucleus
Putamen (Peach Stone)
Globus Pallidus
Lentiform Nucleus
Striatum
Corpus Striatum
Middle Peduncle (Left)
Superior Peduncle (Left)
Inferior Peduncle (Left)
Vermis
Inferior Peduncle (Right)
Superior Peduncle (Right)
Middle Peduncle (Right)
Central Nervous System Line
Meninges Line
Cerebrum Line
Basal Ganglia Line
Gatekeeper Line
Autonomic Loop
Emotions & Learning Line
Cerebellar Line
Cranial Nerve Line
Brainstem Line
Midbrain Line
R.A.S Line
Spinal Line
Cauda Equina Line
CSF Line
Blood Supply Line
Circle of Willis
Vision Line
Trigeminal Branches
L1-L5 Lumbar Spinal Nerves Change here for PNS Nerves
S1-S5 Sacral Spinal Nerves Change here for PNS nerves to suburbs
Coccygeal Spinal Nerve Change for PNS Nerves
Conus Modullaris Spinal Cord & CNS Terminate Here
Filum Terminale
T1-T12 Thoracic Spinal Nerves Change here for PNS nerves to suburbs
C1-C8 Cervical Spinal Nerves Change here for PNS nerves to suburbs
Spinal Cord
Third Ventricle
Brainstem
Cerebellum
Medulla Oblongata
Pyramids Change Here for Contralateral Side
Cerebral Aqueduct
Vertebral Arteries Left & Right
Lungs
Heart
Aorta
Carotid Arteries (Left & Right)
External Catorid Arteries Change for Vessels to Face, Nose, Forehead & Mouth
Reticular Formation
Pons-Medulla Border
Pons
Mandibular Branch
Lower Lip to Chin Sensation & Muscles of Mastication Motor
Lower Eyelid to Upper Lip Sensation
Maxillary Branch
Opthalmic Branch
Forehead Sensation
Fourth Ventricle (Separates Pons & Cerebellum)
Limbic System
Hippocampus Exit for New Learning
Cingulate Gyrus
Amygdala Exit for Emotions
Hypothalamus
Sympathetic Nervous System (Fight or Flight)
Parasympathetic Nervous System (Rest & Digest)
Thalamus
Medial G.N. Auditory
Lateral Geniculate Nucleus Visual Info Here
Basal Ganglia
Anterior Cerebral Arteries
Posterior Cerebral Arteries
Occipital Lobe
Hescl's Gyrus
Wernicke's Area (BA 22)
Temporal Lobe
Lateral Fissure
Cerebral Cortex
Paired Lateral Ventricles
Dura Mater
Meninges
Arachnoid Villi
Skull
Middle Cerebral Arteries
Arachnoid Mater
Sub-Arachnoid Space
Pia Mater
Anterior Cerebral Arteries
Posterior Cerebral Arteries
Basilar Artery
Internal Carotid Arteries (Left & Right)
Superior Colliculus
Inferior Colliculus
Tectum
Red Nucleus
Substantia Nigra
Midbrain
I - Olfactory
II - Optic
III - Occulomotor
IV - Trochlear
V - Trigeminal
VI - Abducens
VII - Facial
VIII - Acoustic (Vestibulocochlear)
IX - Glossopharyngeal
X - Vagus
XI - (Spinal) Accessory
XII - Hypoglossal
Eyes